

Matrix-Associated Chondroplasty: A Novel Platelet-Rich Plasma and Concentrated Nucleated Bone Marrow Cell–Enhanced Cartilage Restoration Technique

Matthias R. Steinwachs, M.D., Bernhard Waibl, M.D., Stephanie Wopperer, M.D., and Marcus Mumme, M.D.

Abstract: Bone marrow stimulation techniques such as microfracture for the treatment of articular cartilage defects so far solely reproduce mechanically inferior fibrous cartilage tissue, which might result in unsatisfactory clinical results at midterm. The combination of microfracture and biomaterials—for example, autologous matrix-induced chondrogenesis technology—has not yet proved that the disadvantages of the marrow stimulation techniques can be overcome. At present, only laboratory-cultivated autologous chondrocytes are able to restore a biomechanically superior cartilage layer and might lead to superior functional results. However, the costs are high and the patient must undergo a 2-stage procedure. By selecting the appropriate cell fraction in conjunction with a controlled release of differentiating growth factors, sufficient cartilage regeneration might be achievable on the basis of bone marrow aspirate as well. We thus describe an advanced surgical technique for the treatment of articular cartilage defects based on platelet-rich plasma and bone marrow aspirate concentrate to overcome these drawbacks.

Articular cartilage defects virtually have no self-healing capacity. As a consequence, a surgical approach for symptomatic grade III or IV defects is required. The most frequently used bone marrow–based cartilage restoration technique is the microfracture technique introduced by Steadman et al.¹ The limitations of this technique are a high rate of intralesional new bone formation² or progressive ossification of the regenerate tissue and limited biomechanical tissue properties (e.g., formation of fibrous cartilage).³

The autologous matrix-induced chondrogenesis (AMIC) technique tried to overcome these limitations by covering the prepared cartilage defect with a type I/III collagen membrane to support differentiation of the mesenchymal stem and stromal cells toward hyaline cartilage. The midterm results of this technique

nevertheless show that this goal likely will not be achieved in most cases.⁴

The aforementioned findings might be at least partially due to a limited number of bone marrow stem cells migrating into the surgically prepared cartilage defect after multiple perforations of the subchondral lamina. The limited bone marrow volume of the patella might aggravate this restriction. Another factor might be the limited access to growth factors promoting tissue

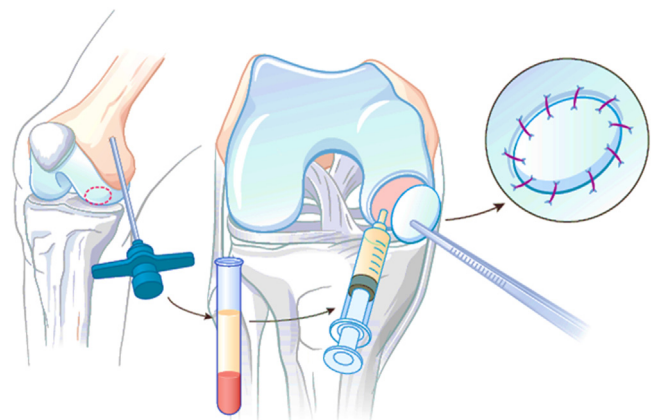


Fig 1. Key principles of MACH. Repair of the cartilage defect is initiated by use of BMAC from the distal femur and PRP from the peripheral blood, as well as coverage with a type I/III collagen membrane (Chondro-Gide).

From the Center of Orthobiologics and Cartilage Repair, Schulthess Klinik, Zürich, Switzerland.

The authors report that they have no conflicts of interest in the authorship and publication of this article.

Received September 3, 2013; accepted January 7, 2014.

Address correspondence to Matthias Reinhard Steinwachs, M.D., Center of Orthobiologics and Cartilage Repair, Schulthess Klinik, Lengghalde 2, 8008 Zürich, Switzerland. E-mail: matthias.steinwachs@kws.ch

© 2014 by the Arthroscopy Association of North America. Open access under CC BY-NC-ND license.

2212-6287/13639

<http://dx.doi.org/10.1016/j.eats.2014.01.002>

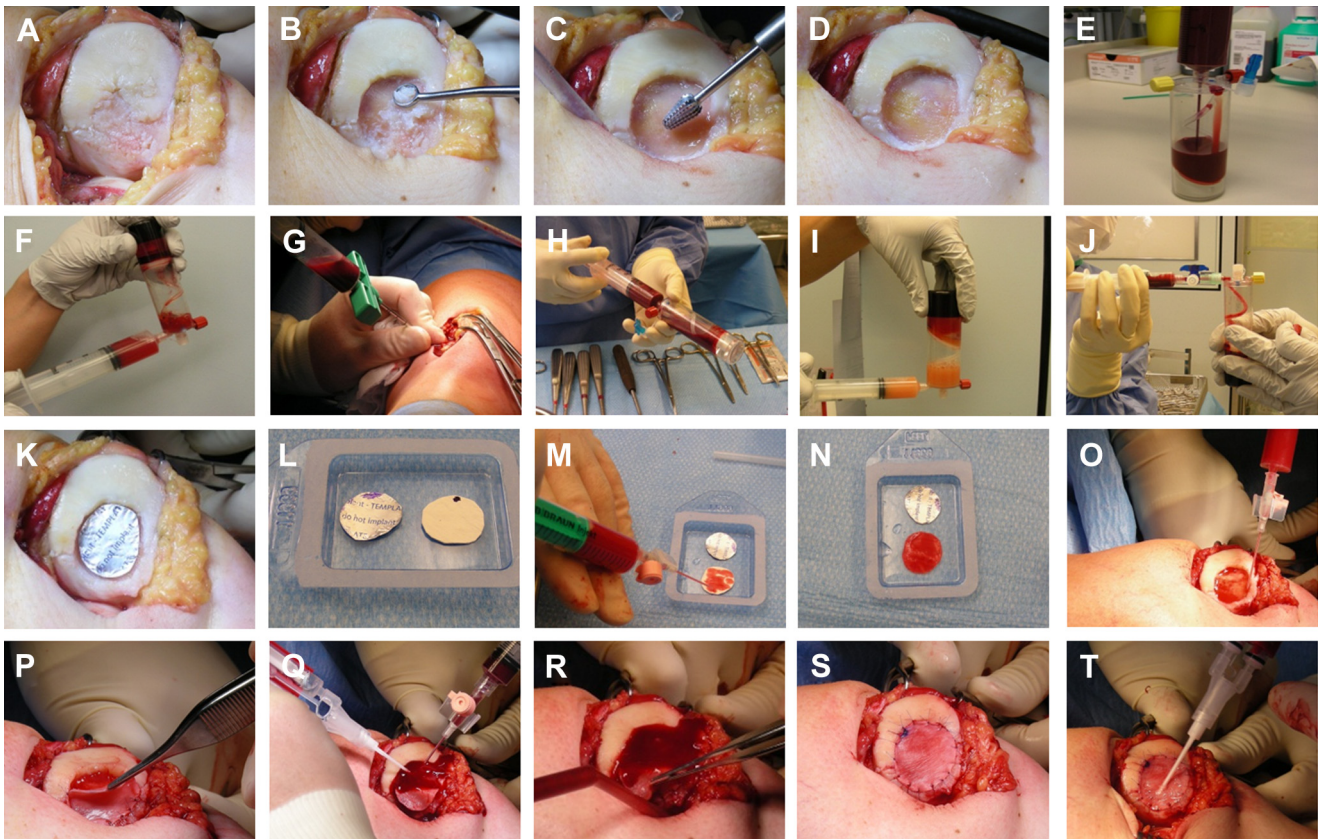


Fig 2. Key steps of MACH. (A) The cartilage defect is prepared by (B–D) removal of all damaged and degenerated cartilage tissue down to the subchondral lamina. (E) For preparation of PRP, 54 mL of venous blood is obtained in a syringe preloaded with 6 mL of citrate anticoagulant (GPSIII Disposable Single Kit) and injected into a special chamber. (F) After a centrifugation step (GPSIII centrifuge), the platelet-poor plasma is discarded and the PRP can be allocated in a syringe. (G) For preparation of BMAC, 24 mL of bone marrow is obtained from the distal femur with a Yamshidi needle in a syringe preloaded with 6 mL of citrate anticoagulant (MarrowStim Mini Concentration System) and (H) injected into a special chamber. After a centrifugation step (GPSIII centrifuge), (I) the cell-poor plasma is discarded and (J) the BMAC is allocated in a syringe. (K) A footprint of the defect is prepared with an aluminum template (included in Chondro-Gide), and (L) the type I/III collagen membrane (Chondro-Gide) is shaped to the footprint. (M, N) The collagen membrane is soaked with PRP, as is (O) the subchondral lamina of the defect. (P) The wet collagen membrane is placed onto the defect and partially fixed with sutures, and (Q) the BMAC is then injected into the defect and stabilized with fibrin adhesive. (R) The stable clot is fully covered with the membrane, (S) which is fixed with sutures and (T) covered with fibrin adhesive.

regeneration and thus leading to a relatively undifferentiated repair tissue formation. Furthermore, the violation of the subchondral bone creates bridging between the bone marrow and joint space, resulting in oxygenation of the defect area, which might be disadvantageous for the generation of the repair tissue.⁴

Table 1. Advantages and Disadvantages of MACH

Advantages	Disadvantages
One-step surgery	Increased operative time
No injury to subchondral bone	Slightly more complex surgical technique
Standardized volume of BMAC injected into cartilage defect	No long-term data
Promotion of cell differentiation by growth factors in PRP	

Autologous chondrocyte implantation (ACI)⁵ has proved to partially avoid the degeneration of repair tissue and change in phenotype (from cartilage-like tissue toward bone) over time and to produce, in many cases, regenerate tissue quite similar to hyaline joint cartilage histologically with superior mechanical properties.³ The flaws of this technique are the expense and the need for a 2-stage procedure.

Thus we propose a new approach based on platelet-rich plasma (PRP) and bone marrow aspirate concentrate (BMAC) to solve the dilemma of unpredictable tissue formation in marrow stimulation techniques and to avoid the drawbacks of ACI.

Centrifugation of bone marrow aspirate has proved to be able to multiply the bone marrow–derived mesenchymal stem and stromal cells and therefore might provide an adequate number of cells initiating cartilage-like

Table 2. Tips for MACH

Tips	Reasons
Prepare PRP and BMAC in a timely manner.	The centrifugation steps take 15 min each and could delay surgery.
Debride all damaged and degenerated cartilage tissue down to the subchondral lamina.	Damaged tissue might compromise repair tissue formation and lead to failure.
Avoid injury to the subchondral bone.	Injury might lead to bone pathology, chronic bone reaction, or conduction.
Prepare a footprint of the cartilage defect with an aluminum template, and shape the collagen membrane according to the template.	Using a template reduces the risk of an inaccurately shaped collagen membrane.

tissue formation.⁶ Centrifuged peripheral blood is able to deliver a high number of platelets rich in growth factors known to promote cell differentiation and cell metabolism⁷⁻⁹ (transforming growth factor β 1, bone morphogenetic proteins 2 and 7, insulin-like growth factor 1, and so on). This assumption should be true especially in lesions of the joint cartilage of the patella, in which the number of stem cells is equally limited as are the perfusion and therefore inflow of growth factors

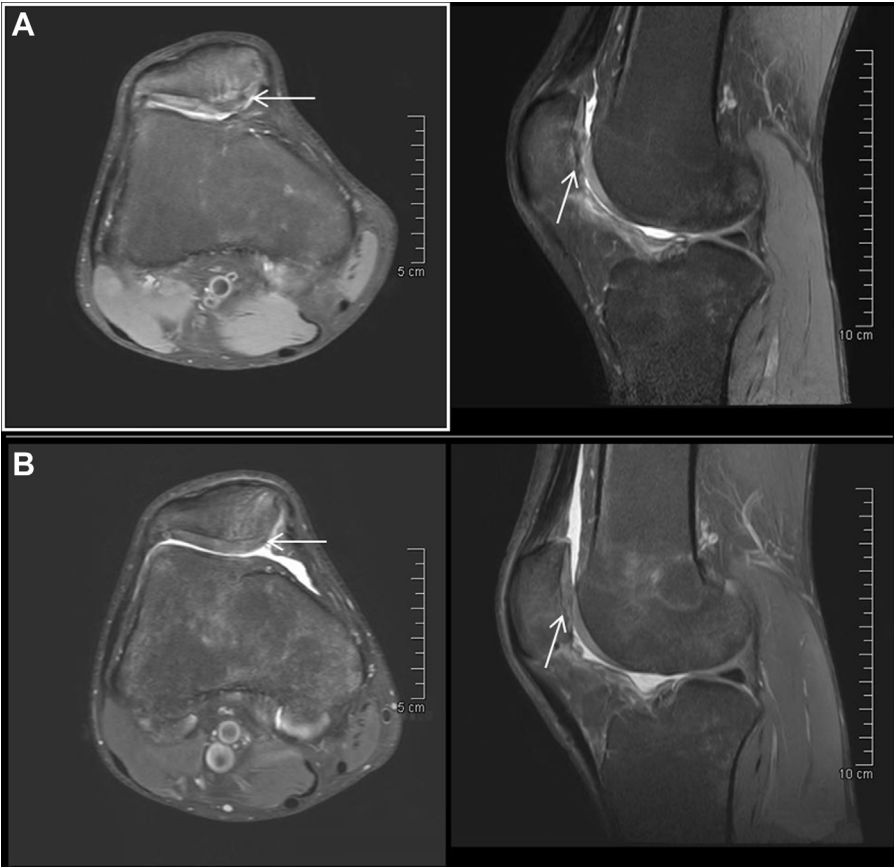after perforation of the subchondral bone. The surgical approach to induce mechanically and histologically superior regenerate tissue formation is based on delivery of a high concentration of these potentially beneficial mesenchymal stem and stromal cells and growth factors into the defect, avoiding penetration of the subchondral bone and consequently the contamination of the defect with bone marrow blood of low regenerative capacity. The ease and speed of the 1-step AMIC procedure are retained by this modification.

Technique

Similar to other marrow stimulation techniques, matrix-associated chondroplasty (MACH) is a 1-step procedure. The key principles are shown in Fig 1.

The defect is exposed by arthrotomy (Fig 2A), either medial for the patella and/or trochlea or lateral/medial for the femoral condyles, and the borders of the cartilage defect are prepared with respect to containment, removing all damaged and degenerated cartilage tissue down to the subchondral lamina (Figs 2B-2D). In contrast to the microfracture and AMIC techniques, perforation or abrasion of the subchondral bone is not desired to avoid injury to the bone, which can lead to bone pathology or chronic bone reaction. The violation of the subchondral bone might result in a

Fig 3. Axial (left) and sagittal (right) views of magnetic resonance imaging (echo-planar diffusion weighted sequence, fat-suppressed) (A) before and (B) 8 months after MACH for failed AMIC surgery. The magnetic resonance imaging results indicate good integration and filling of the retropatellar defect (arrows). The subchondral bone edema is markedly reduced 8 months after surgery.



disadvantageous oxygenation of the repair area and initiate intralesional new bone formation (Table 1).

In parallel, the PRP is prepared. Fifty-four milliliters of venous blood is obtained in a syringe preloaded with 6 mL of citrate anticoagulant (GPSIII Disposable Single Kit; Biomet, Warsaw, IN). After a centrifugation step at 3,200 rpm for 15 minutes (GPSIII centrifuge; Biomet) in a special chamber to separate the red blood cells, platelet-poor plasma, and PRP, the platelet-poor plasma is discarded and the PRP is allocated in a syringe (Figs 2E and 2F).

After PRP preparation, 24 mL of bone marrow is obtained from the distal femur with a Yamshidi bone marrow needle in a syringe preloaded with 6 mL of citrate anticoagulant (MarrowStim Mini Concentration System; Biomet) (Figs 2G and 2H). The bone marrow can also be obtained arthroscopically before arthrotomy. After a centrifugation step at 3,200 rpm for 15 minutes (GPSIII centrifuge) to separate the red blood cells, cell-poor plasma, and BMAC, the cell-poor plasma is discarded (Fig 2I) and the BMAC is allocated in a syringe (Fig 2J).

After the preparation of the PRP and BMAC, an aluminum template (included in Chondro-Gide; Geistlich, Wolhusen, Switzerland) according to the cartilage defect size and shape is created (Figs 2K and 2L) and transferred onto the collagen membrane (Chondro-Gide). Optimal fitting of the dry membrane into the defect is then ensured, respecting a swelling of the membrane of approximately 10% after loading with the PRP concentrate. The membrane has a smooth side and a porous side. The smooth side is impermeable for cells. The porous side of the membrane is gently moistened with the growth factors drop by drop to ensure equal fluid distribution and absorption by the collagen membrane (Figs 2M and 2N). This absorption process takes about 5 to 10 minutes. The subchondral bone of the cartilage defect is also moistened with the PRP (Fig 2O). After this is accomplished, the membrane should feel like a gelatinous canvas and can be partially sutured (No. 6-0 Monosyn; B Braun, Melsungen, Germany) into the defect (Fig 2P). The bone marrow concentrate is then injected into the cartilage defect and forms a stable clot with the addition of fibrin adhesive (Tisseel; Baxter, Deerfield, IL) (Figs 2Q and 2R). The membrane is fixed totally to the defect and stabilized by fibrin adhesive (Tisseel) (Figs 2S and 2T). Stable circular fixation should be ensured to avoid delamination during the early rehabilitation phase. After joint irrigation and insertion of an intra-articular drain, the arthrotomy is closed in a standard fashion. The surgical technique is demonstrated in Video 1. The most important tips for this surgical technique are summarized in Table 2.

Discussion

The advancement of marrow stimulation techniques is crucial to overcome the drawbacks of existing techniques,

such as unpredictable tissue formation and intralesional osteophyte formation. The proposed MACH technique might improve the formation of regeneration tissue by providing a sufficient number of potent mesenchymal progenitor cells from BMAC and encouraging cell differentiation mediated by growth factors available in the autologous PRP. Avoiding subchondral bone injury might prevent negative subchondral effects. On the other hand, MACH is a new surgical technique lacking data about its long-term safety and efficacy especially in comparison with other surgical techniques such as AMIC or ACL.

Nonetheless, the preliminary results of the first treated patients indicate the feasibility of the MACH technique because good defect filling and integration of the repair tissue can be obtained (Fig 3). However, further clinical studies are required to prove the superiority of this technique over the existing marrow stimulation techniques.

References

1. Steadman JR, Rodkey WG, Singleton SB, Briggs KK. Microfracture technique for full-thickness chondral defects: Technique and clinical results. *Oper Tech Orthop* 1997;7:300-304.
2. Mithoefer K, McAdams T, Williams RJ, Kreuz PC, Mandelbaum BR. Clinical efficacy of the microfracture technique for articular cartilage repair in the knee: An evidence-based systematic analysis. *Am J Sports Med* 2009;37:2053-2063.
3. Saris DB, Vanlauwe J, Victor J, et al. Treatment of symptomatic cartilage defects of the knee: Characterized chondrocyte implantation results in better clinical outcome at 36 months in a randomized trial compared to microfracture. *Am J Sports Med* 2009;37(suppl 1):10S-19S.
4. Kusano T, Jakob RP, Gautier E, Magnussen RA, Hoogewoud H, Jacobi M. Treatment of isolated chondral and osteochondral defects in the knee by autologous matrix-induced chondrogenesis (AMIC). *Knee Surg Sports Traumatol Arthrosc* 2012;20:2109-2115.
5. Brittberg M, Lindahl A, Nilsson A, Ohlsson C, Isaksson O, Peterson L. Treatment of deep cartilage defects in the knee with autologous chondrocyte transplantation. *N Engl J Med* 1994;331:889-895.
6. Fortier LA, Potter HG, Rickey EJ, et al. Concentrated bone marrow aspirate improves full-thickness cartilage repair compared with microfracture in the equine model. *J Bone Joint Surg Am* 2010;92:1927-1937.
7. Boswell SG, Cole BJ, Sundman EA, Karas V, Fortier LA. Platelet-rich plasma: A milieu of bioactive factors. *Arthroscopy* 2012;28:429-439.
8. Fortier LA, Barker JU, Strauss EJ, McCarrel TM, Cole BJ. The role of growth factors in cartilage repair. *Clin Orthop Relat Res* 2011;469:2706-2715.
9. Milano G, Deriu L, Sanna Passino E, et al. Repeated platelet concentrate injections enhance reparative response of microfractures in the treatment of chondral defects of the knee: An experimental study in an animal model. *Arthroscopy* 2012;28:688-701.